

## IMAGE CHALLENGE

## Collapse in the scrum

## CLINICAL INTRODUCTION

A 17-year-old male patient was brought by ambulance to the ED following a witnessed collapse while playing rugby. He denied any significant trauma, chest pain or breathlessness, and was alert and uncomplaining on arrival, with normal observations and a normal physical exam. Witnesses described a loss of consciousness, with a period of respiratory arrest requiring rescue breaths at the scene. Paramedics reported frequent ventricular extrasystoles on their arrival.

The patient had no medical history and was on no medication, although admitted to 'fainting' some 3 weeks previously, again while playing rugby. A paternal uncle had died suddenly at the age of 45.

His initial ECG is shown in [figure 1](#).

## QUESTION

What is the most likely diagnosis?

- Pulmonary embolism (PE)
- Hypertrophic obstructive cardiomyopathy (HOCM)
- Arrhythmogenic right ventricular cardiomyopathy (ARVC)
- Right ventricular outflow tract tachycardia (RVOT)

For answer see [page 772](#)

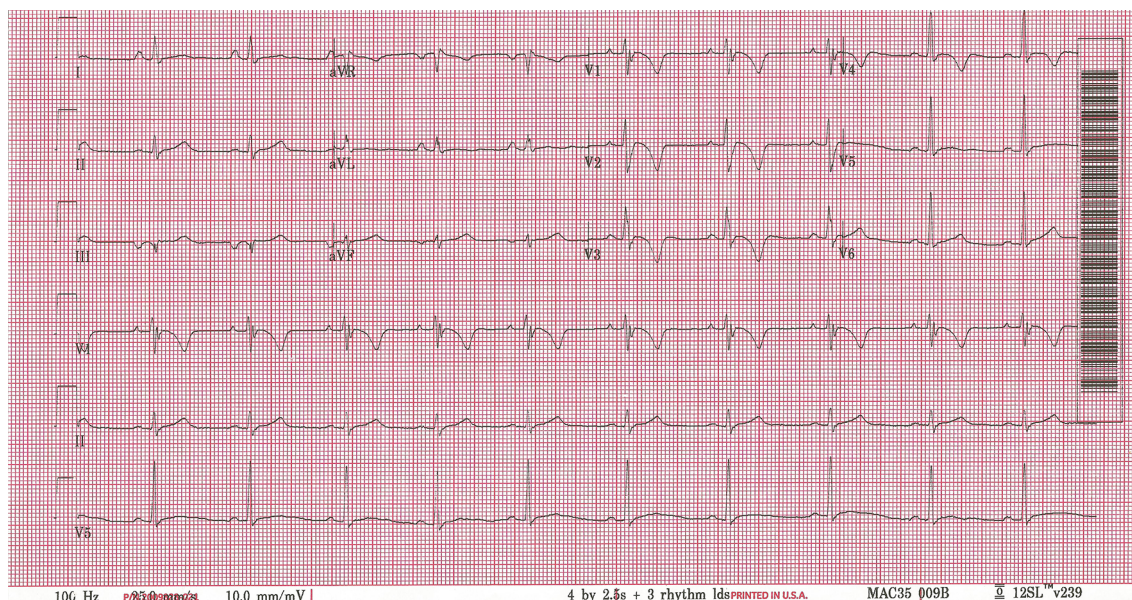


Figure 1 Initial ECG.

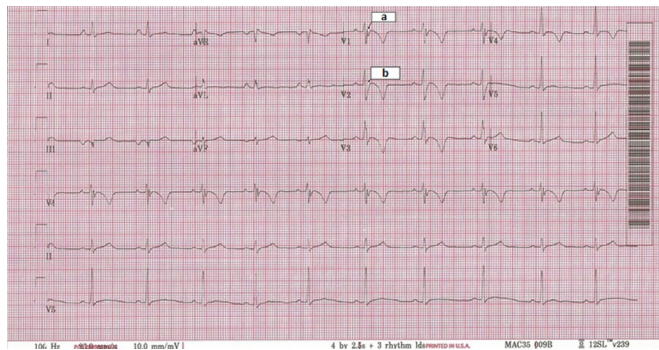
# Collapse in the scrum

For question see page 764

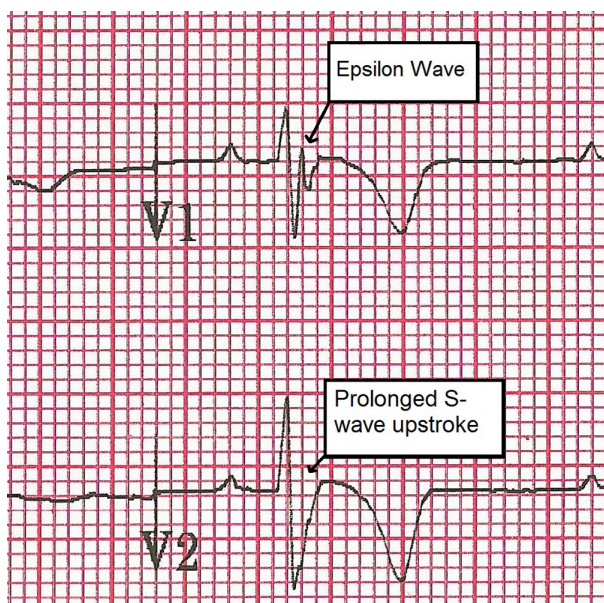
## ANSWER: C

The ECGs (figures 2 and 3) show deep T-wave inversion in V1–V4, a prolonged S-wave upstroke in V2 and an epsilon wave (small positive deflection at the end of the QRS complex) evident in V1. The patient was referred to the cardiology team. Transthoracic echo confirmed right ventricular (RV) dilatation and pulmonary hypertension with a normal left ventricle. The echo and ECG findings suggested ARVC. This was subsequently supported by cardiac MRI.

ARVC is the second most common cause of sudden cardiac death (SCD) in the under 35 age group (after HOCM).<sup>1</sup> It



**Figure 2** Annotated ECG showing epsilon wave (a), prolonged S-wave upstroke (b) and T-wave inversion in V1–V4.



**Figure 3** Enlarged ECG image of V1 and V2.

is an autosomal dominantly inherited condition in around one-third of cases, characterised by fibro-fatty tissue replacement of the RV wall, predisposing to RV dilatation and SCD from sustained ventricular tachyarrhythmia.

Diagnosis is via complex scoring system including ECG and cardiac imaging.<sup>2</sup> Most cases will have ECG abnormalities at presentation, including a prolonged S-wave upstroke (>55 ms) in V1–V3 in 90%, inverted T-waves in V1–V3 in 50% and an epsilon wave in V1–V2 in 33%.

PE would be unlikely given the history and lack of risk factors. HOCM would show characteristic echocardiographic changes, while the ECG classically shows features of left ventricular hypertrophy (LVH) and deep Q-waves in lateral and inferior leads. RVOT is considered to be a primary electrical phenomenon, with a broad complex tachycardia of left bundle branch block (LBBB)-like morphology and right axis deviation on ECG, in the absence of structural heart disease.<sup>1</sup>

The patient was unable to tolerate beta-blockers and was referred for implantable cardioverter defibrillator (ICD) placement. He has been advised against playing competitive rugby.

David Donnelly,<sup>1</sup> David Patrick,<sup>1</sup> Robin A Weir<sup>2</sup>

<sup>1</sup>Emergency Department, Hairmyres Hospital, East Kilbride, UK

<sup>2</sup>Cardiology Department, Hairmyres Hospital, East Kilbride, UK

**Correspondence to** Dr David Donnelly, Emergency Department, Hairmyres Hospital, Eaglesham Road, East Kilbride, G75 8RG, Scotland; david.donnelly@lanarkshire.scot.nhs.uk

**Correction notice** This article has been corrected since it published Online First. The name of the last author (Robin A Weir) has been corrected.

**Contributors** DD assessed the patient in the ED and planned the article. DP and RW assisted in writing the article.

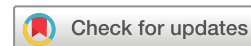**Funding** This research received no specific grant from any funding agency in the public, commercial or not-for-profit sectors.

**Competing interests** None declared.

**Patient consent** Obtained.

**Provenance and peer review** Not commissioned; internally peer reviewed.

© Article author(s) (or their employer(s) unless otherwise stated in the text of the article) 2018. All rights reserved. No commercial use is permitted unless otherwise expressly granted.



**To cite** Donnelly D, Patrick D, Weir RA. *Emerg Med J* 2018;**35**:772.

Accepted 13 February 2018

Published Online First 5 March 2018

*Emerg Med J* 2018;**35**:772.

doi:10.1136/emered-2017-207434

## REFERENCES

- Romero J, Mejia-Lopez E, Manrique C, et al. Arrhythmogenic Right Ventricular Cardiomyopathy (ARVC/D): A Systematic Literature Review. *Clin Med Insights Cardiol* 2013;**7**:CMC.S10940–114.
- Marcus FI, McKenna WJ, Sherrill D, et al. Diagnosis of arrhythmogenic right ventricular cardiomyopathy/dysplasia: proposed modification of the task force criteria. *Circulation* 2010;**121**:1533–41.

